

**Emboso<sup>soft</sup>**  
Microspheres

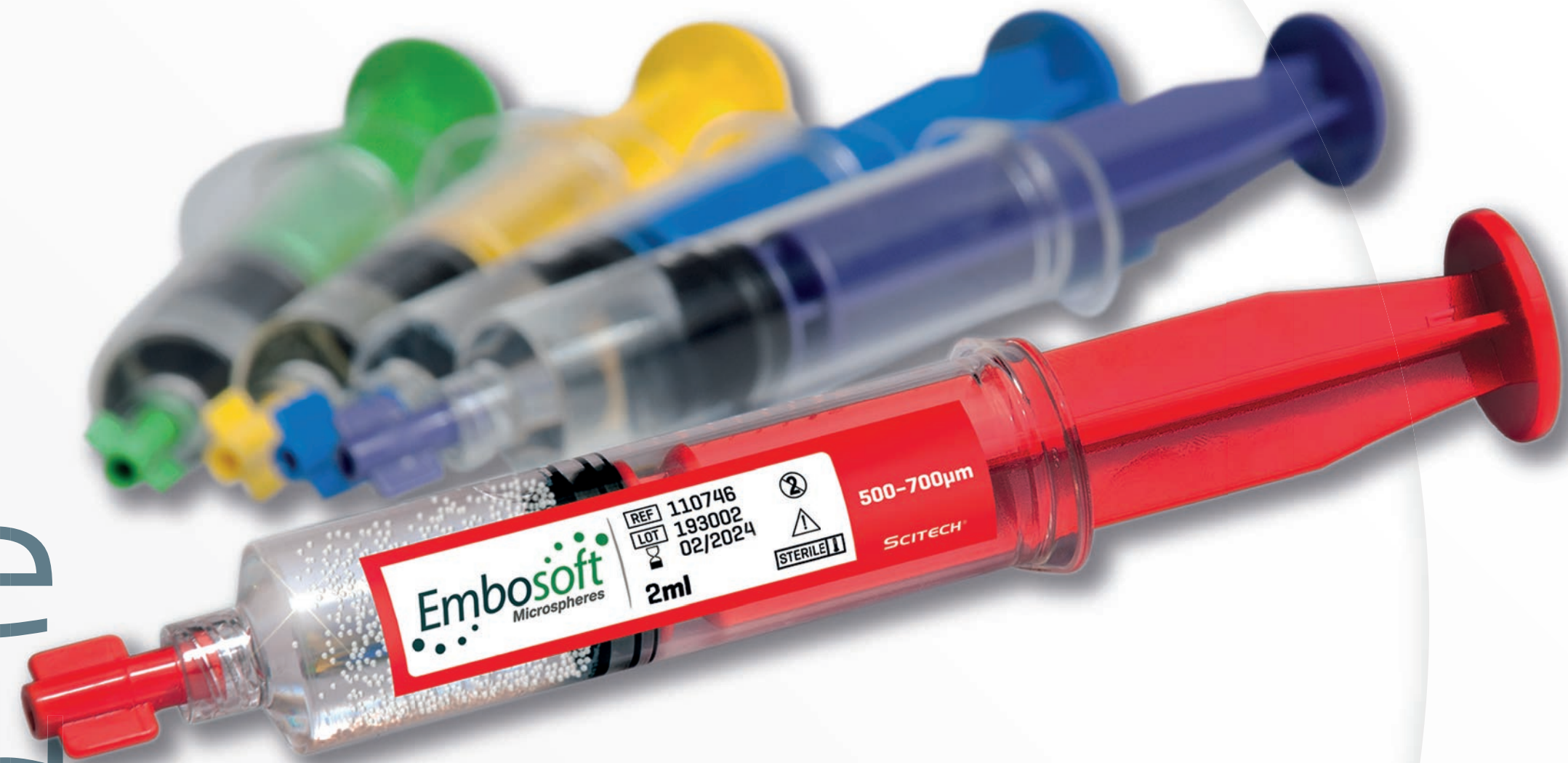

**SCITECH**<sup>®</sup>  
Innovation for Life

## Characteristics:

- Smooth microcatheter passage
- Low risk of catheter obstruction
- Effective targeted Embolization
- 5 different size ranges
- Higher Uniformity Shape

# Effective targeted Embolization





## Indications:

- Hypervascular tumor embolization;
- Symptomatic uterine fibroids embolization;
- Prostatic arteries for the relief of symptoms related to Benign Prostatic Hyperplasia (BPH) embolization;
- Haemostatic embolization.



# 5 different size ranges

Embosoft microspheres are available in 5 different size ranges, identified by color:


					
Range:	100-300µm	300-500µm	500-700µm	700-900µm	900-1100µm
Minimum ID Microcatheter:	0.43mm - 0,017"	0.53mm - 0,021"	0.61mm - 0,024"	0.71mm - 0,028"	1.020mm - 0,040"

# Unique Material: Polifit 70®

Embosoft microspheres are composed of exclusive Polifit 70®, a homogeneous blend material developed by Scitech, which guarantees a well-defined spherical shape and a high level of compressibility.

Bench tests demonstrated the capacity to reduce its size by up to 36% without compromising the integrity on its return to the original spherical shape, demonstrating resistance to deformation, resistance to fragmentation and viscoelasticity in line with competitors.

up to **36%**  
of elastic  
compression\*



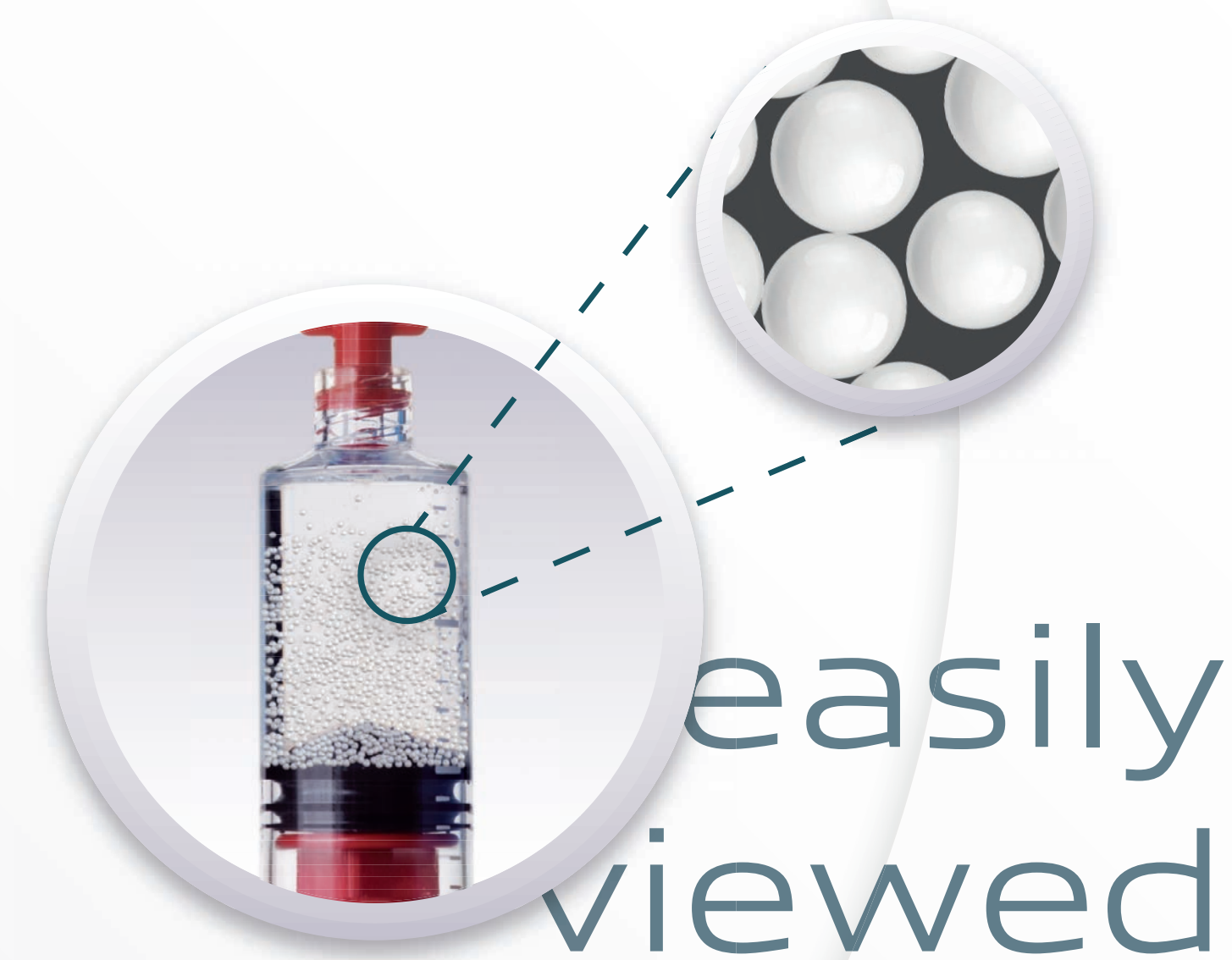
Hydrophilic surface  
More flexible

\*for 500-700µm size range

# Low risk of microcatheter clogging

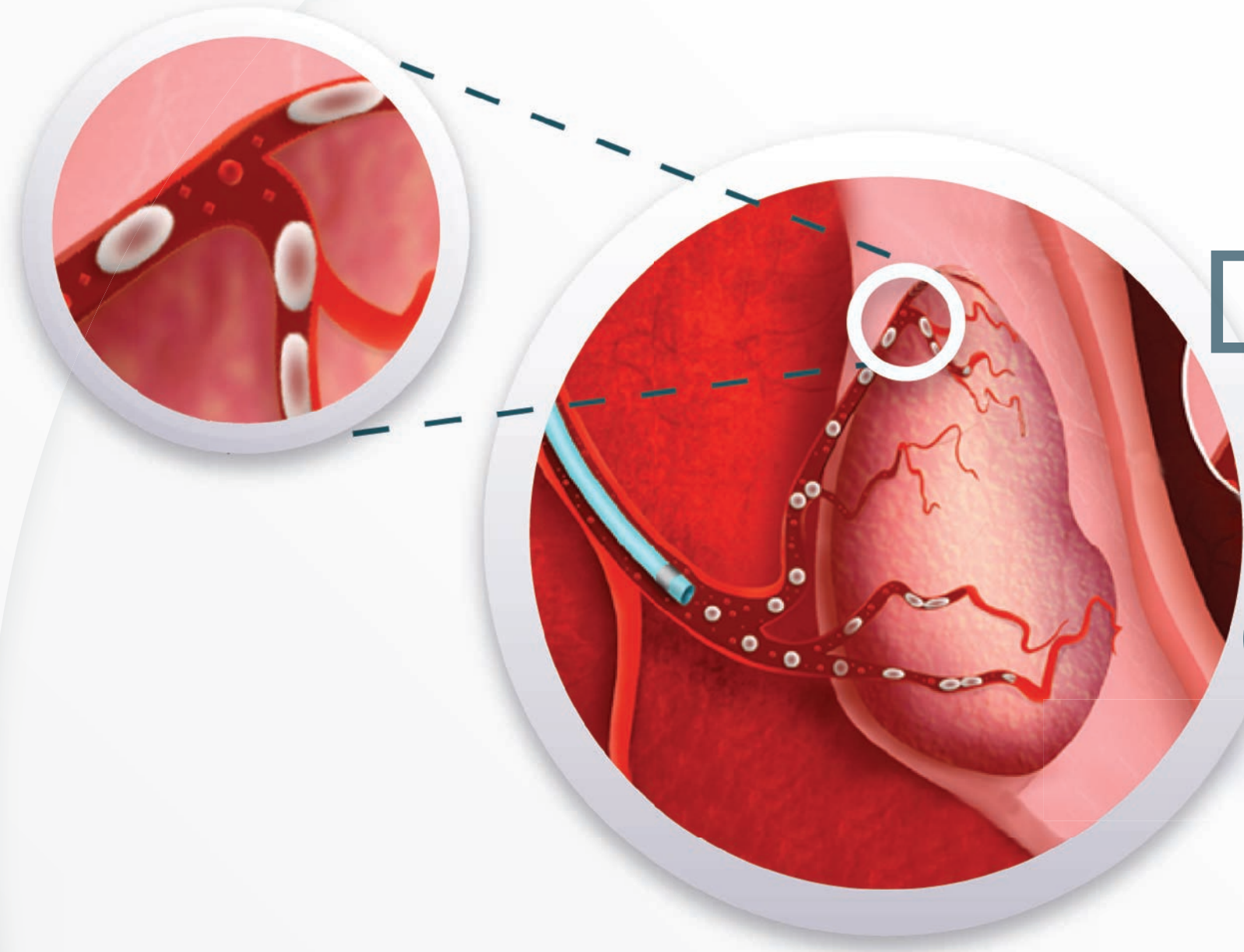


Inject the Embosoft/contrast medium solution in small proportions, slowly and gently, using a 1ml to 5ml injection syringe in order to line up the microspheres through the microcatheter lumen.



## easily viewed

Due to its light color, the Embosoft Microspheres are easily viewed during the injection



# Distal and selective embolization

Due to the characteristics of Embosoft microspheres, a distal and selective embolization is possible.

## Clinical Investigation Summary

Uterine artery embolization with microspheres in patients with Leiomyoma (EMBOSOFT I Study).

**Objective:** To evaluate the therapeutic response to uterine artery embolization in patients with leiomyoma using the microspheres Embosoft®.

**Design:** Prospective, single-arm, open label study - 30 participants.

Complete study information at:  
[www.clinicaltrials.gov](http://www.clinicaltrials.gov) - NCT03535610

## Uterine Artery Embolization with Microspheres for Treatment of Leiomyoma and Adenomyosis.

Dr. Denis Szejnfeld<sup>1</sup>

### CASE REPORT:

A 43-year-old patient presenting hypermenorrhea and menorrhagia for 3 years. Initially treated with COC (Combined oral contraceptive) with partial success in bleeding control. At the time of consultation, the patient presented iron deficiency anemia (Hb 9.2 mg / dL) under treatment with ferrous sulfate. Patient without previous surgical treatment for fibroid and without comorbidities. Patient with two previous pregnancies at term, uneventful (the last one was 15 years ago). The patient underwent MRI showing 6 intramural fibroids between 0.7 and 2.3 cm and diffuse adenomyosis with junctional zone thickening with a maximum thickness of 2.3 cm. Uterine volume of 286 cm<sup>3</sup>.

### EMBOLIZATION PROCEDURE:

Right femoral arterial access followed by angiographic studies and superselective atherization of the left and right uterine arteries. Embolization was performed with 1 Embosoft® 300 – 500 µm microspheres syringe and 1 500 - 700 µm syringe on each side to the point of near stasis of the main trunk and maintenance of the cervicovaginal branches.

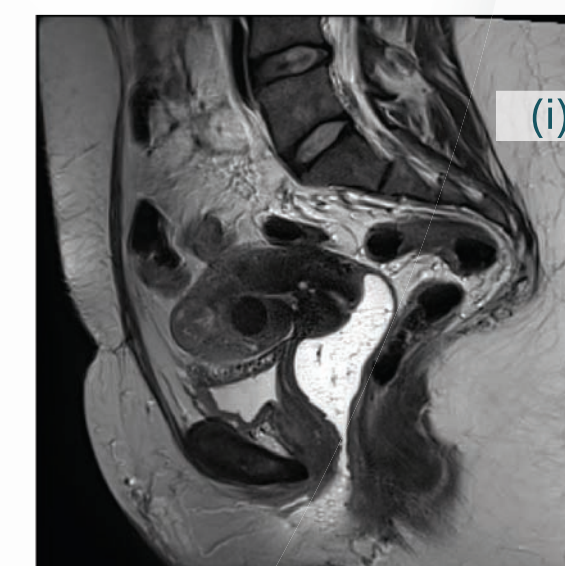
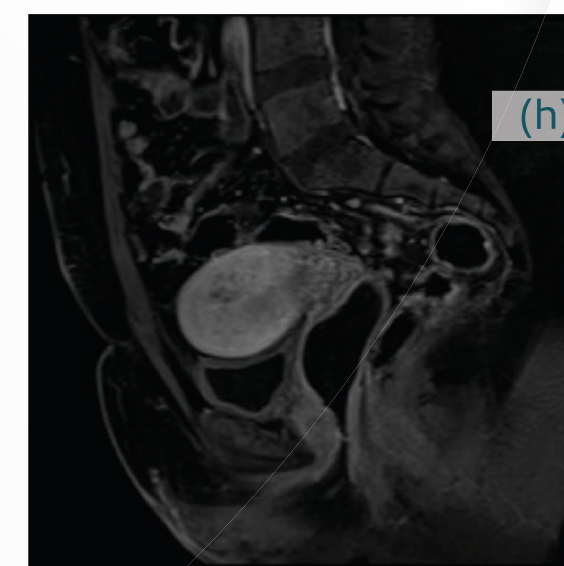
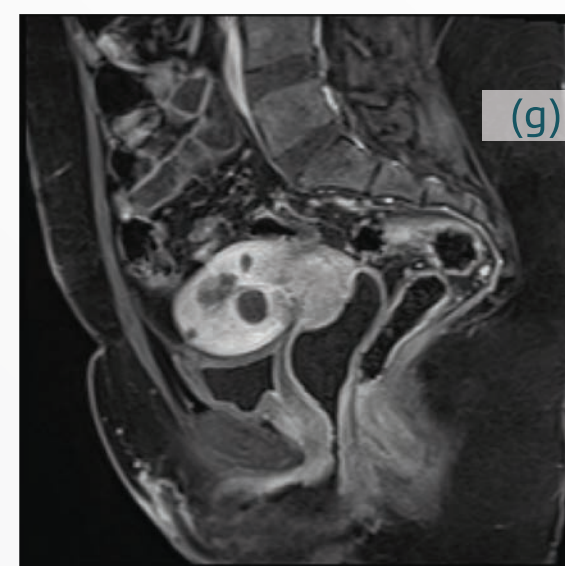
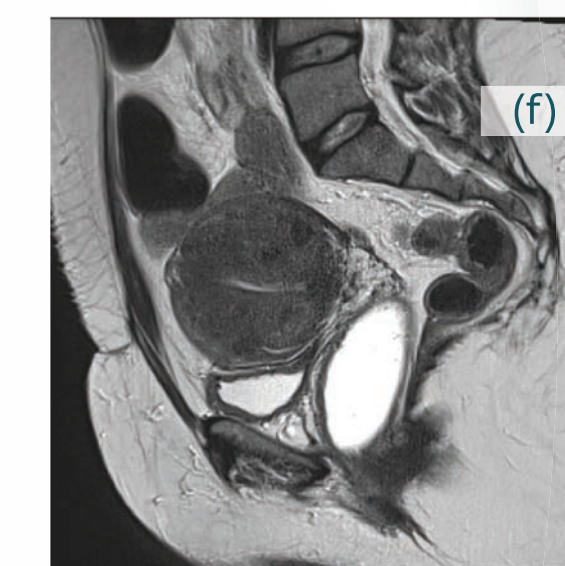
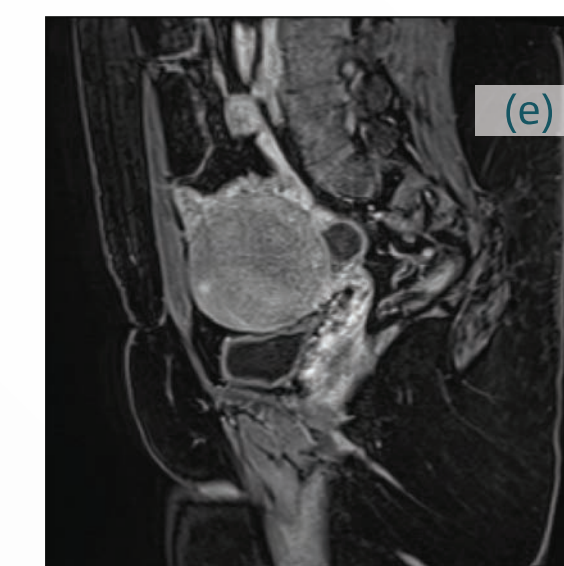
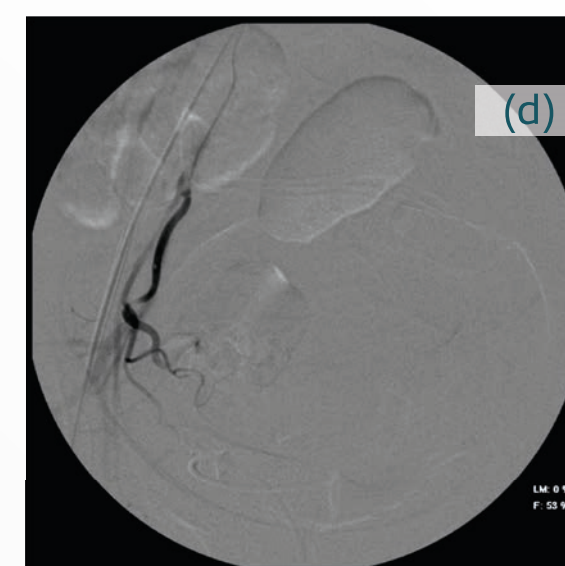
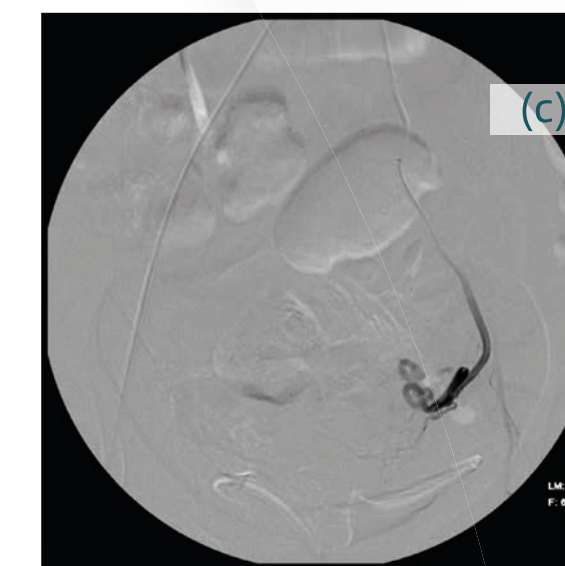
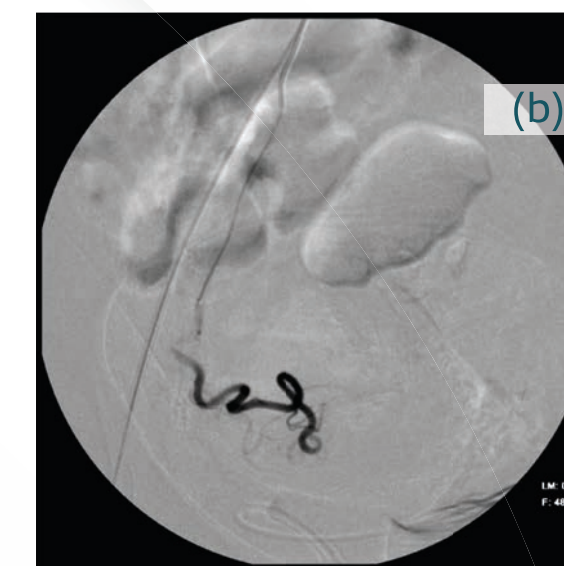
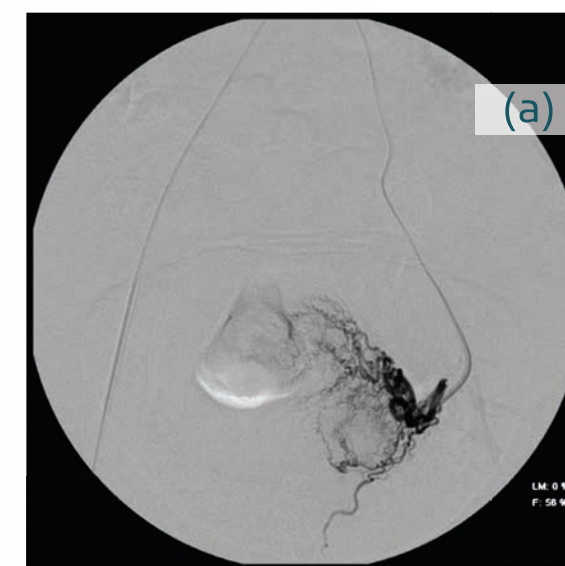
### EVOLUTION:

Patient evolved uneventfully and was discharged the day after the procedure. Evolution in the first 4 days with NSAID-controlled pain. 6-month MRI after the embolization procedure showing all fibroids with 100% necrosis and significant reduction in the junctional zone (9 mm in the control study). Uterine volume of 103 cm<sup>3</sup> (Initial volume of 286 cm<sup>3</sup>). Patient presented total regression of symptoms, presenting 3-day cycle with small amount of menstruation).

### IMPRESSION:

In this case, it can be observed that the association of Embosoft® 300-500 and 500-700 microspheres was effective and safe in the embolization of the fibroids and also of denomyosis with satisfactory radiological and clinical evolution.

Pelvic angiography demonstrates superselective catheterization of the left (A) and right (B) uterine arteries. Angiographic controls demonstrate absence of hypervascularization and preservation of the left (C) and right (D) uterine arteries. Pre-embolization pelvic MRI with multiple hypervascularized myomatous nuclei (E, F). MRI after embolization. There is a complete absence of contrast uptake by the fibroids and improvement of adenomyosis (G, H, I).



<sup>1</sup> Hospital Certa – São Paulo - SP

## Embolization of Uterine Fibroids with Microspheres for Treatment of Leiomyoma.

Dr. Marcus Vinicius Borges<sup>1</sup>

### BACKGROUND:

Patient, 43 years old, diagnosed with uterine fibroids since 2012, initially asymptomatic. She developed hypermenorrhea and increased abdominal volume, pollakiuria and discomfort during sexual intercourse. Imaging studies revealed fibroid growth.

The patient underwent hysteroscopic resection of submucosal fibroid and evolved without resolution of the bleeding. Uterus with volume of 390 cm<sup>3</sup> and multiple images of fibroids, the largest being 44 cm<sup>3</sup>.

### METHODS:

Femoral access to the right.

Superselective catheterization of uterine arteries.

Right and Left Uterine Artery Embolization with Embosoft® 500 – 700 µm Microspheres.

### RESULTS:

Magnetic resonance imaging about 12 months after the embolization procedure showed complete infarction of the fibroids (absence of contrast uptake) and reduction of the fibroid size and uterine volume (from 400 to 234 cm<sup>3</sup>).

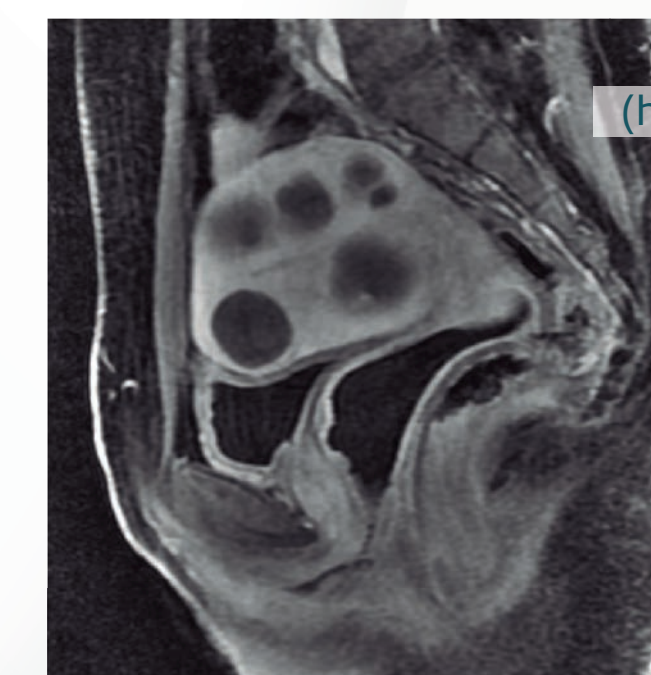
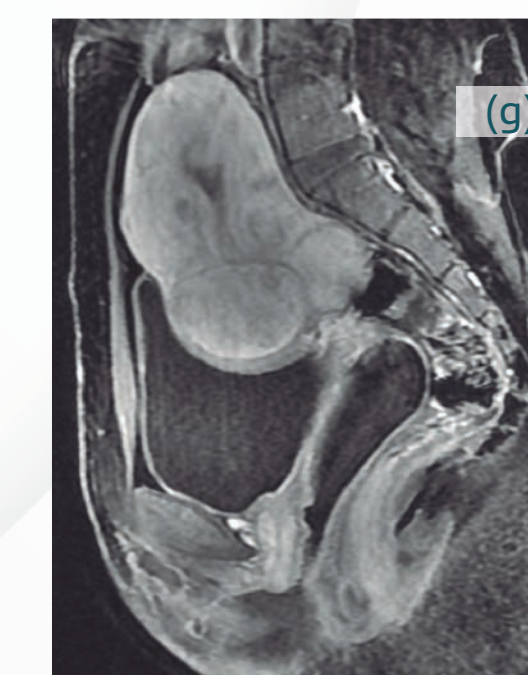
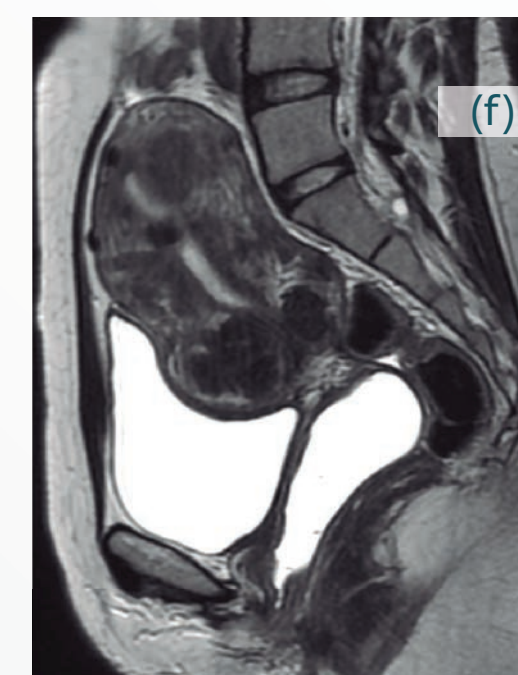
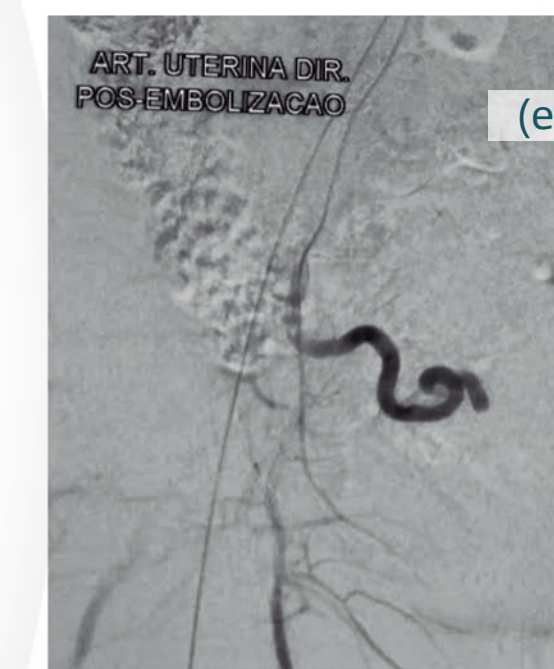
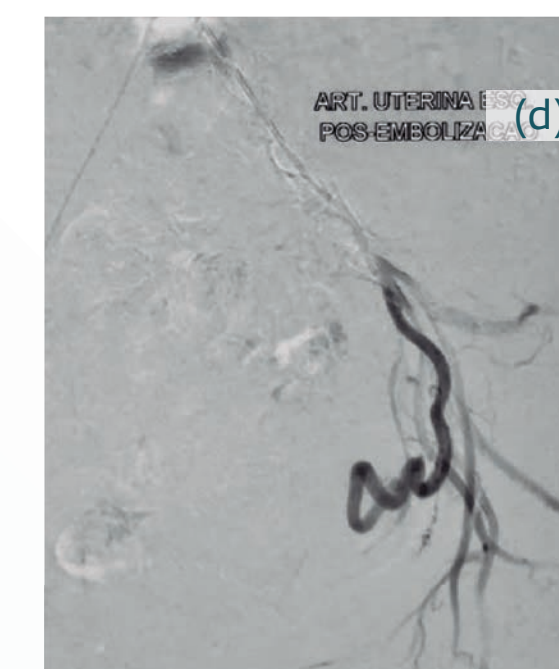
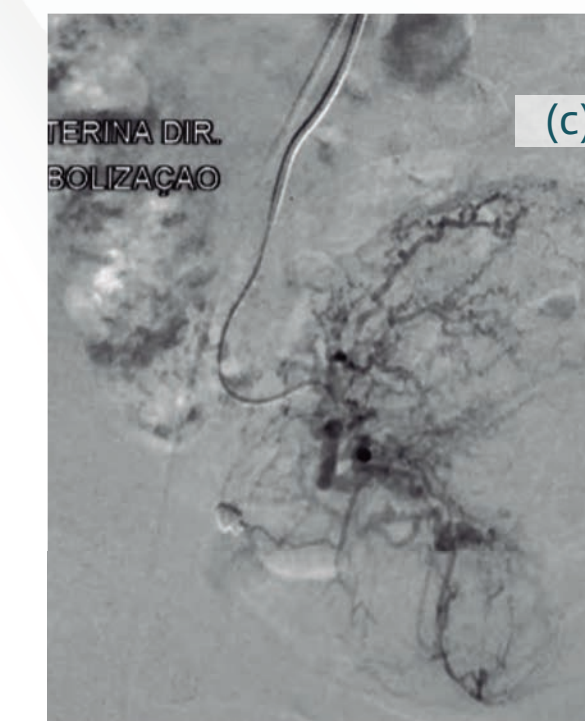
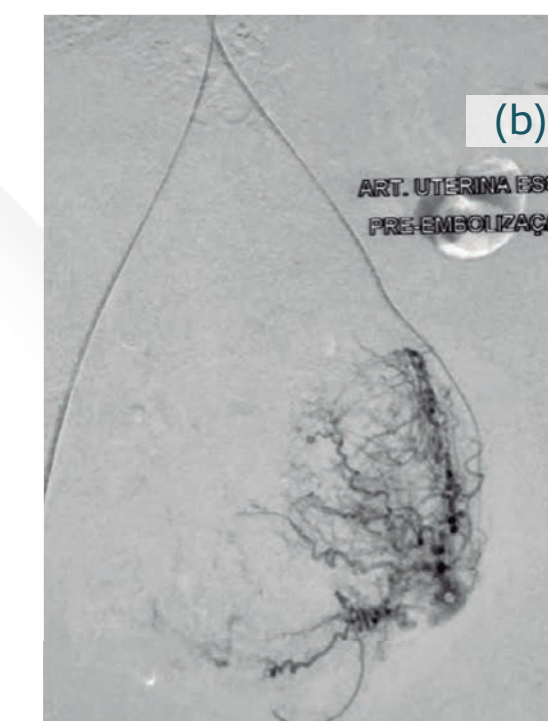
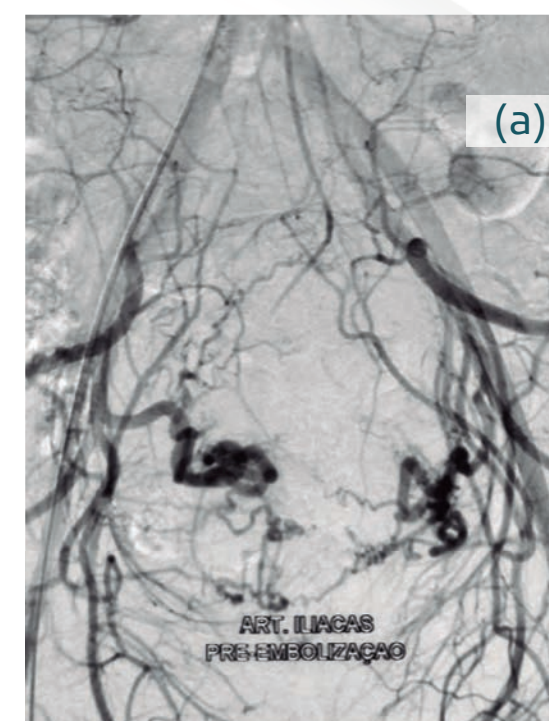
### CONCLUSIONS:

The embolization procedure of the uterine arteries using Embosoft® microspheres was effective in devascularization and subsequent infarction of the fibroids, as well as a clear reduction in uterine volume..

Panoramic angiography of the pelvis shows patent, enlarged and tortuous uterine arteries. (a); Superselective catheterization of the left (b) and right (c) uterine artery (hypervascularized myomatous nodules).

Angiographic controls demonstrate complete absence of opacification of previously described hypervascularized lesions (b and c) and preservation of the left (d) and right (e) uterine arteries. Pre-embolization pelvic MRI with multiple hypervascularized myomatous nuclei (f and g).

MRI post embolization. A complete absence of contrast uptake by the fibroids (h) is noted.



<sup>1</sup> Hospital Aliança - Salvador - BA

## Ordering Information

Range ( $\mu\text{m}$ )	Reference
100-300	128288
300-500	128289
500-700	128290
700-900	128291
900-1100	128292

Volume: 2ml



[www.scitechmed.com](http://www.scitechmed.com)